

# Midline diastema closure with direct-bonding restorations

Author\_ Dr Sushil Koirala, Nepal

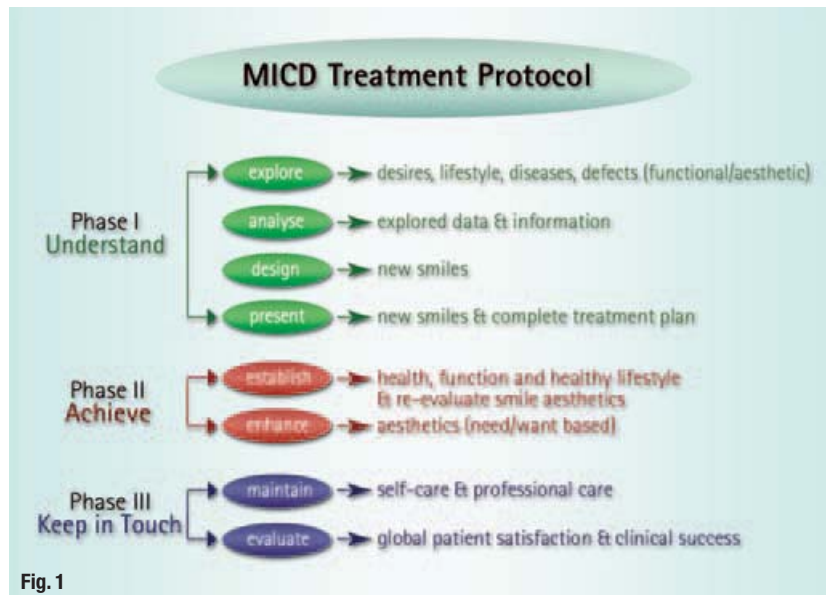


Fig. 1

**Fig. 1\_MICD TP.** **\_Midline diastemata (MD)** are spaces of varying magnitude between the crowns of fully erupted maxillary and mandibular central incisors. Keene describes MD as anterior midline spacing greater than 0.5 mm between the proximal surfaces of adjacent teeth. Incidences of maxillary and mandibular MD are 14.8 and 1.6 %, respectively.<sup>1</sup>

MD can occur in temporary, mixed or permanent dentition and may be considered normal for many children during the eruption of the permanent maxillary central incisors. When incisors first erupt, they may be separated by bone and the

crowns incline distally because of the crowding of the roots. With the eruption of the laterals and permanent canines, the MD reduces or even closes completely.

### Etiological factors

The etiological factors of MD are described by various researchers. Angle concludes the presence of an abnormal frenum to be the cause of MD,<sup>2</sup> a view that has been supported by other researchers.<sup>3-5</sup> According to Tait, the frenum is the effect and not the cause of the incidence of diastemata.<sup>6</sup> He reports causes such as ankylosed central incisors, flared or rotated central incisors, anodontia, macroglossia, dento-alvolar disproportion, localised spacing, closed bite, facial type, ethnic and genetic characteristics, inter-premaxillary suture and midline pathology. Weber lists the causes for spacing between maxillary incisors as the result of high frenum attachment, microdontia, macrognathia, supernumerary teeth, peg laterals, missing lateral incisors, midline cysts, habits such as thumb-sucking, mouth breathing and tongue thrusting.<sup>7</sup> Therefore, the etiological factors can be summarised as follows:

1. developmental: microdontia, missing laterals, mesiodens, macroglossia, macro-hypertrophic fibrous frenum;
2. pathological: midline cysts, tumours and periodontitis;
3. neuromuscular: oral habits, such as tongue thrusting during speech, swallowing or abnormal pressure during rest.

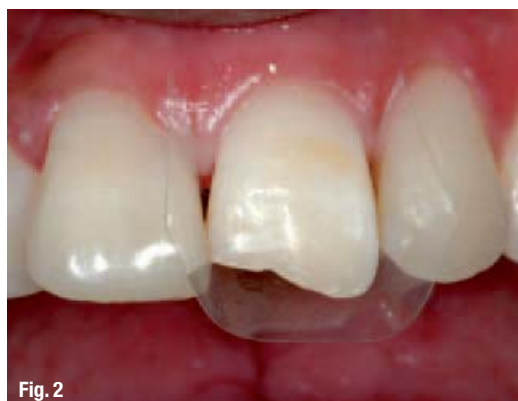

Fig. 2

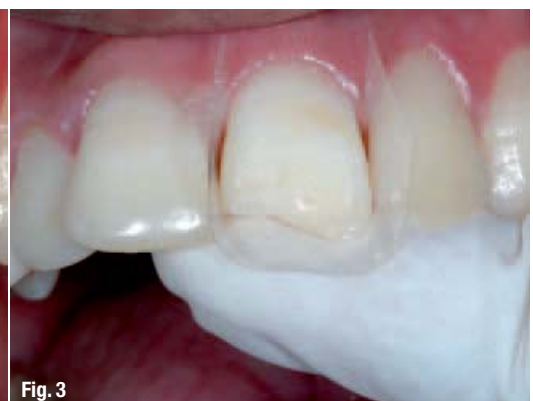

Fig. 3

Fig. 2\_Placement of plastic strip.

Fig. 3\_Plastic strip is supported with index finger.

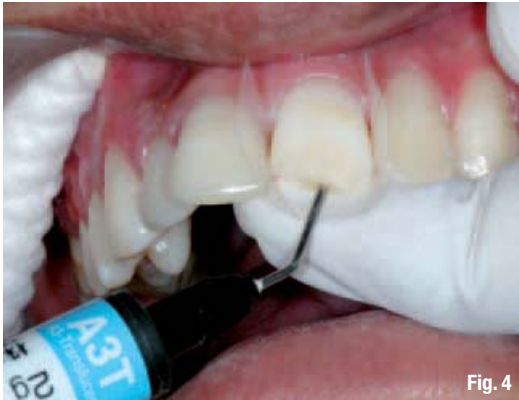

Fig. 4

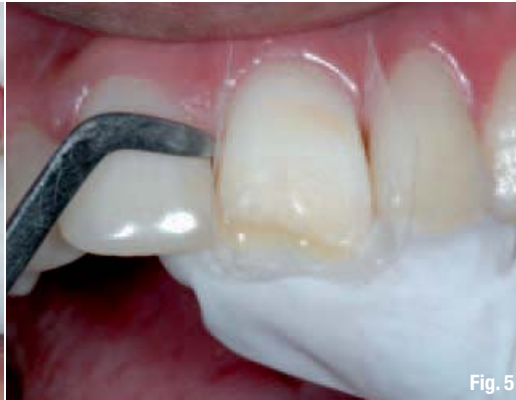

Fig. 5

Fig. 4 \_Injection of flowable resin to create frame.

Fig. 5 \_Flowable resin ready for light curing.

Clinicians must be prepared for patients visiting the dental office with the aim of having their diastema closed in order to fulfil their psychological (aesthetic and beauty enhancement), functional (pronunciation of 'f' and 's' sounds and cutting foods with anterior teeth) and/or health (oral-health maintenance) problems.

### \_Treatment options for diastema closure

Treatment modalities depend on the etiological factors and complexity of the MD. It is suggested that treatment of a MD should be delayed until the eruption of the permanent canines. However, the pathological causes should be ruled out and treated at an early stage, for example extraction of supernumerary teeth (mesiodens) and surgical treatment for the removal of midline cyst, tumour and periodontal pathologies. Surgical, orthodontic (comprehensive/short term), periodontal, direct-bonding and indirect restorations are the treatment modalities that can be used alone or in combination to achieve harmony in terms of a patient's aesthetics, function and health.

MICD by definition is "a holistic approach that explores the smile defects and aesthetic desires of a patient at an early stage and treats them using the least intervention options in diagnosis, treatment and maintenance technology by considering the

psychology, health, function and aesthetics of the patient."<sup>8</sup> The MICD concept as the professional movement that encourages all clinicians to select diagnosis, treatment and maintenance modalities that are the least invasive in order to preserve healthy oral tissues while still achieving the natural aesthetics outcome in the best interests of the patient's health and happiness.

Following, I will demonstrate the clinical use of MICD TP (minimally invasive cosmetic dentistry treatment protocol) to close or reduce the diastema in clinical practice (Fig. 1).<sup>8</sup> The direct-bonding procedure with the application of the Flowable Frame Technique (FFT) is presented here as a special technique.<sup>9</sup>

### \_Case presentation

A 20-year-old female patient presented with the complaint that she did not like her smile because of the large gap between her upper front teeth. The patient was very concerned about her smile aesthetics and also aware of her speech difficulties.

#### *Phase I: Understand*

In the first step of Phase I, the patient's perception, lifestyle, personality, and desires were explored in a personal interview and through completion of the *MICD self smile-evaluation form*. The patient,

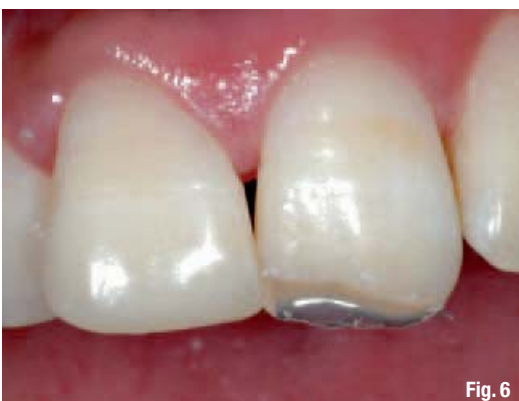

Fig. 6

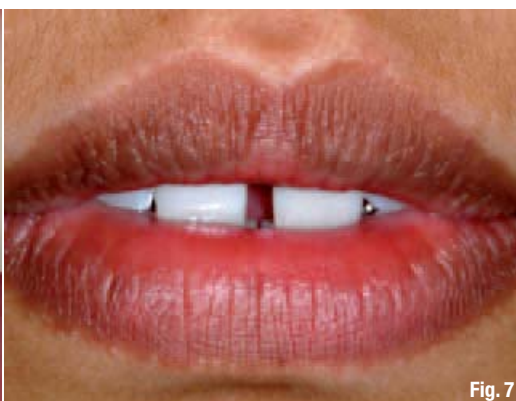

Fig. 7

Fig. 6 \_Plastic strip is removed after light curing; note beautiful lingual frame.

Fig. 7 \_Lips at rest; note MD is clearly visible.

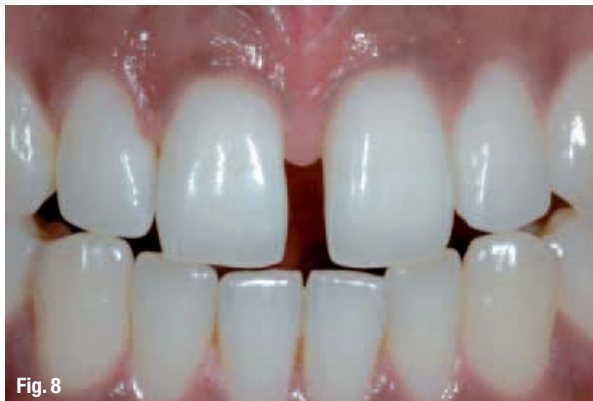

Fig. 8

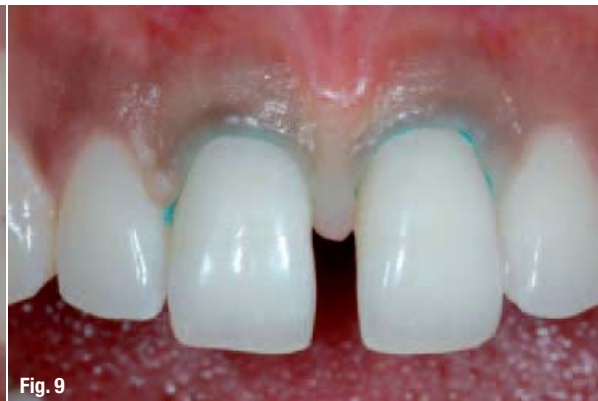

Fig. 9

**Fig. 8** \_MD in close-up view.  
**Fig. 9** \_Teeth #12 and 21 after isolation with gingival retraction cords.

who exhibited a high dental IQ, evaluated her smile as below satisfactory.

After the interview, the disease, force element and aesthetic defects of her smile were explored clinically. Necessary digital photographs were taken, along with diagnostic study models for further exploration of existing diseases, force elements and aesthetic defects. The patient had good oral health, normal function and no para-functional or other destructive oral habits.

The collected clinical and diagnostic information, such as extra and intra-oral digital photographs, study models and X-rays, was further analysed to determine her smile aesthetic grading in terms of her health, function and aesthetics, as well as to gain an overview of the clinical problems and the macro-, mini- and micro-smile defects. We found a high frenum attachment and the space analysis of the study model revealed a MD of 3.5 mm between teeth #12 and 21. The tooth-size ratio of the centrals was nearly 65 % and lacked central dominance.

**Fig. 10** \_Light touch upon the enamel surface of tooth #12 with diamond point to enhance bonding process.

In the design step, a new smile with a closed gap was designed. It is to be noted that the upper central incisors are considered key to a smile<sup>10,11</sup> and must be given sufficient prominence.<sup>12</sup> The aesthetically acceptable width of the centrals is between 75 % and 80 % of their length.<sup>12</sup> In the presented case,

it was logical to close the diastema completely by increasing the width of the centrals. The types of treatment involved, complexity, possible risk factors, complications and treatment limitation were evaluated, and the tentative costs calculated and presented to the patient.

The new smile was proposed through the modified digital photographs and aesthetic mock-up of the study model. In order to correct her MD, a frenectomy with non-invasive indirect partial veneers was proposed as the first option and a direct-bonding restoration without frenectomy as the second option. However, because of financial constraints, the patient preferred the second option.

All patient queries related to the proposed new smile and treatment modalities were addressed in detail. The informed consent form was signed prior to proceeding to Phase II.

*Phase II: Achieve*

In the first step, the patient's health, function and a healthy lifestyle were established. The patient's smile was graded as Grade B.<sup>8</sup> The established parameters of her oral health and function were within normal limits, the aesthetic parameters were below the accepted level and enhancement treatment was to improve her aesthetic parameters further. Hence,

**Fig. 11** \_Enamel etching with phosphoric acid (FL-Bond Etchant) for 20 seconds.

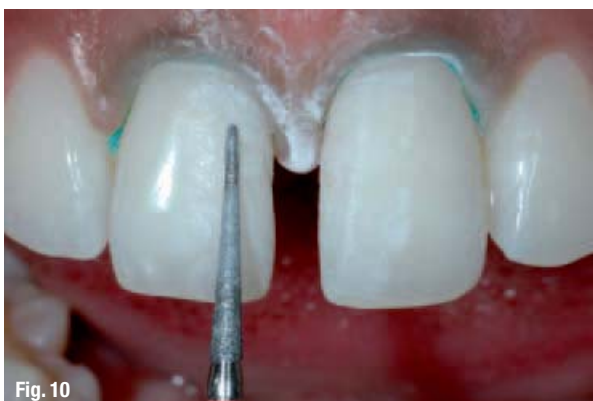

Fig. 10

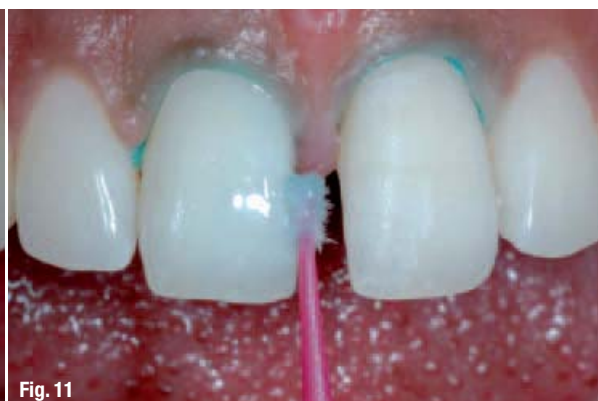

Fig. 11

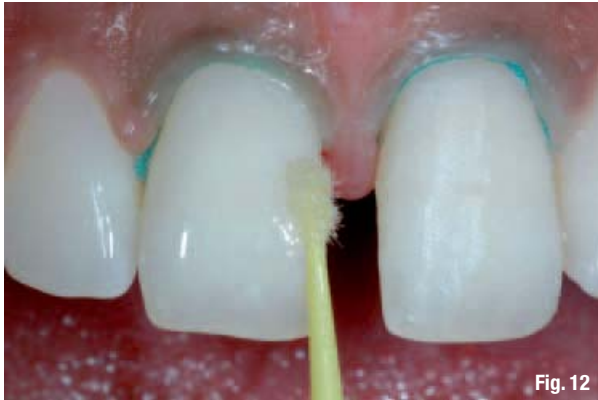

Fig. 12

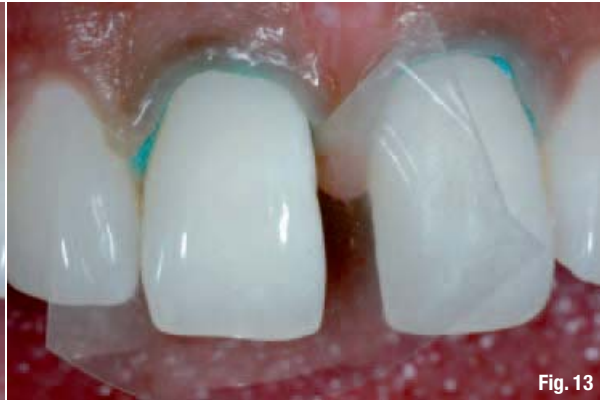

Fig. 13

in this case, it was not necessary to undergo establishment treatment (like orthodontic, periodontal, occlusal adjustment, etc.) before proceeding to the aesthetic enhancement step. According to MICD TP, the desire of the patient in this case was need-based or naturo-mimetic smile enhancement.

### Direct-bonding restoration

The direct-bonding restoration technique represents the preferred therapeutic option in MICD. It preserves maximal tooth structure and helps to restore function and aesthetics in only a few clinical visits. In addition, the technique is economical and the possible need for sophisticated indirect restoration can be postponed. Direct-bonding restorations demand excellent clinical skills. The clinician is required to incorporate various clinical techniques, tips and tricks. Following, I would like to demonstrate a simple technique that I have applied since 2005 in various clinical scenarios and find helpful for the upgrade of clinicians' restorative skills.

#### *The Flowable Frame Technique*

The FFT is a simple restorative technique developed to speed up the placement and simplified confinement of material when restoring challenging anterior aesthetic cases such as large Class IV or Class III defects and diastema closure or reduction. As the name suggests, this technique requires

flowable composite resin as frame material, a plastic strip, composite brush and other usual instruments for direct resin restorations.

#### *Clinical steps in the Flowable Frame Technique*

The following steps are to be taken:

- Step 1—After the completion of etching, priming and bonding of the tooth surfaces, insert a simple plastic strip to the level of gingival sulcus of the tooth to be restored (Fig. 2).
- Step 2—Support the plastic matrix strip lingually with your index finger to create a lingual contour (Fig. 3).
- Step 3—Inject the flowable composite resin of desired shade (either opacious or translucent) and smooth it to a thin layer with a hand instrument or a composite brush if necessary (Fig. 4).
- Step 4—Light cure the flowable composite and remove the plastic strip. A flowable frame is now ready (Figs. 5 & 6). The length, shape and thickness of the flowable frame can be adjusted using the sharp edge of the hand instrument or a diamond point if required.

The advantages of the FFT are:

- time and cost saving (no direct or indirect mock-up required);
- thickness of the layer of restoring materials

**Fig. 12**\_Uniform layer of bonding (FL-Bond) application.

**Fig. 13**\_Placement of plastic strip for FFT.

**Fig. 14**\_Injection of flowable resin (Beautiful Flow shade A3T).

**Fig. 15**\_Adjustment of lingual frame with sharp hand instrument.

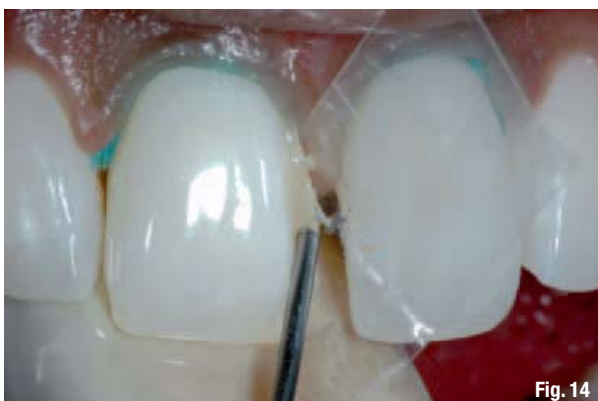

Fig. 14

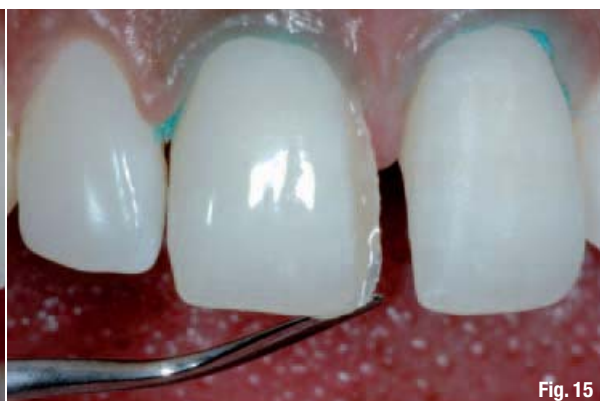

Fig. 15

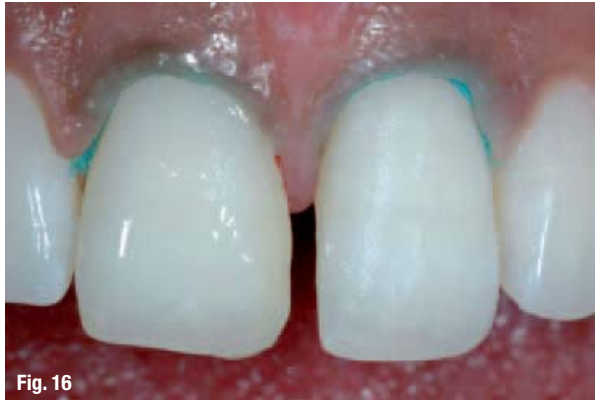

Fig. 16

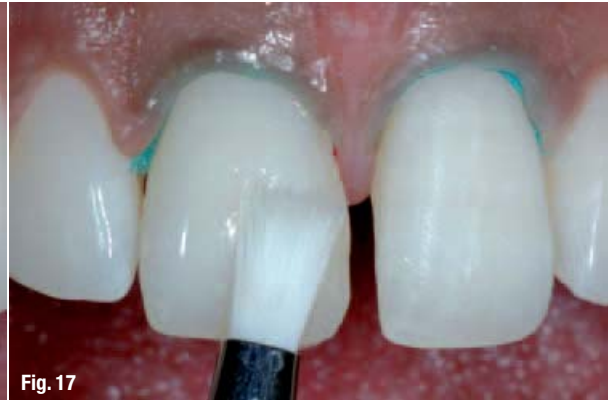

Fig. 17

**Fig. 16** Application of Beautiful II dentine shade A1.

**Fig. 17** Dentine layer is smoothed with a brush and light cured.

**Fig. 18** Application of enamel layer in Beautiful II shade Inc.

**Fig. 19** Tooth #12 after final restoration.

**Fig. 20** Lingual frame created on tooth #21.

**Fig. 21** Teeth #12 and 21 after finishing and polishing.

(dentine, enamel and opacious group) can be predicted; as with the silicone template method, an opaque halo, mamelons, and translucent areas in the proximal and incisal areas can be created; smooth palatal surface is achieved with minimal finishing; smooth adaptation of the restorations can be achieved even in the gingival sulcus; and it is the most suitable lingual frame creation technique for diastema reduction or closure.

### Material selection and clinical steps for diastema closure

Material selection for diastema closure should be guided by optical properties (light transmission

and diffusion characteristics) and tissue responses of the materials (restoration in diastema closure normally touches the gingival tissue and sulcus). Amongst the various materials available, Giomers are amongst the latest category of micro-hybrid light-cured restorative materials and are touted as the true hybridisation of glass ionomers and composite resins, as they have the fluoride release and recharge of glass ionomers and the aesthetics (shade, polish and optical properties), handling and physical properties of composite resins. Gioner restorative and adhesive systems have good bio-compatibility<sup>13</sup> and have been reported not to result in long-term post operative sensitivity.<sup>14</sup> They have also been found to possess anti-plaque formation properties.<sup>15</sup> Hence, gioner direct-restorative materials and adhesive systems were selected to close the MD in this case.

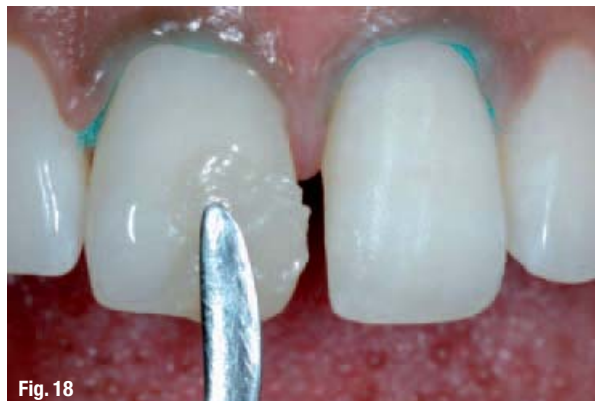

Fig. 18

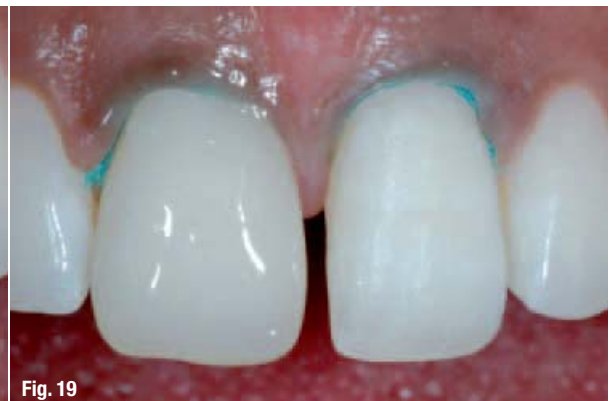

Fig. 19

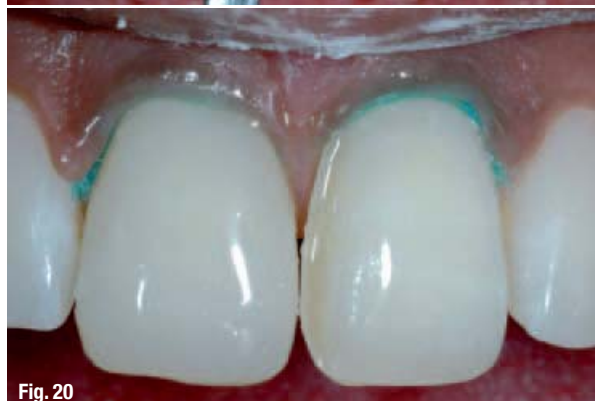

Fig. 20

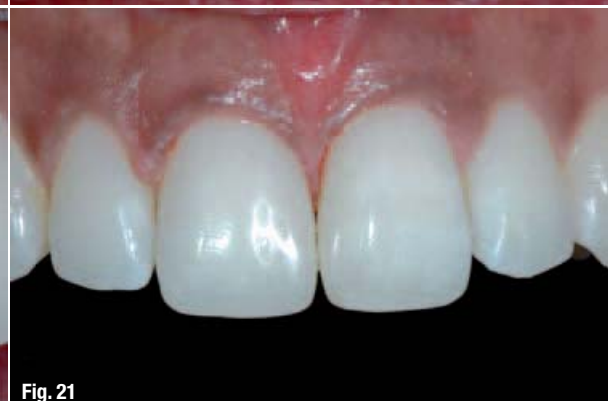

Fig. 21

Beautiful Flow Shade #A3T with giomer adhesive system FL-Bond II (SHOFU Inc.) were used in FFT to create the lingual frame. Beautiful II (SHOFU Inc.) dentine shade A1 and enamel shade Inc. were used to restore the defects using the bi-layered shading technique to achieve the desired aesthetics with an invisible restoration. The Direct Cosmetic Restoration Kit and the Super-Snap Rainbow Technique Kit (both SHOFU Inc.) were used to prepare the teeth and to finish and polish the final restorations (Figs. 7–22).

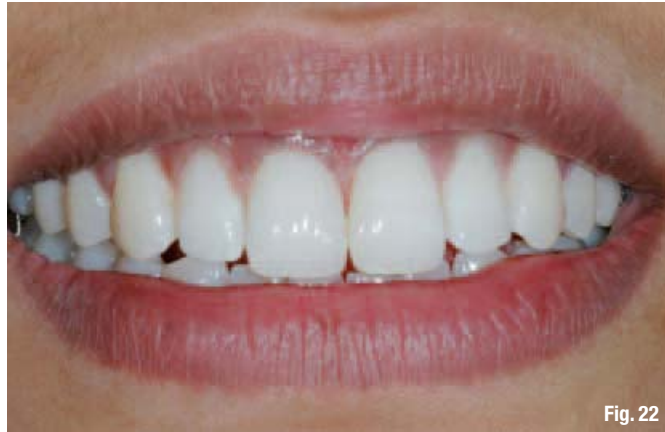

Fig. 22

*Phase III: Keep in touch*

After completion of the treatment, the importance and role of the keep-in-touch concept to the long-term success of aesthetic enhancement procedures were briefly explained to the patient. She was advised to continue her normal oral hygiene procedures and shown how to keep the interdental space of the closed diastema clean. In the final step of MICD TP, the patient was requested to fill out the *MICD clinical evaluation form*. The patient evaluated her new smile as excellent and mentioned that she was fully satisfied with the overall clinical services at our centre. The *MICD summary ten* (Table I →) helps to evaluate the overall success of the case.

time and costs involved. The MICD TP guides the clinician and the patient and helps both to understand, plan and complete the clinical case using diagnosis and treatment modalities that are the least invasive in order to preserve sound tooth structure and achieve natural aesthetics, considering the patient's best interests.

Fig. 22\_Final smile.

**Conclusion**

Diastema closure or reduction in clinical practice requires detailed case analysis. The successful treatment of diastemata depends on etiological factors, size and extent of the diastema, and the patient's affordability in terms of treatment

**MICD summary ten**

1. SMILE SELF-EVALUATION: BELOW SATISFACTORY
2. SMILE GRADE: B
3. TREATMENT CATEGORY: TYPE I
4. TREATMENT COMPLEXITY: GRADE I
5. PROPOSED TREATMENT: ACCEPTED
6. ESTABLISHMENT OUTCOME: NOT APPLICABLE (N/A)
7. SMILE RE-EVALUATION: N/A
8. ENHANCEMENT CATEGORY: NATURO-MIMETIC (NEED-BASED)
9. EXIT REMARKS: EXCELLENT
10. CLINICAL SUCCESS: SATISFACTORY

Table I

*Editorial note: A complete list of references and the MICD forms are available from the publisher.*

**\_about the author**



**Dr Sushil Koirala** is the founding president of the Vedic Institute of Smile Aesthetics and the chief instructor of Comprehensive Aesthetic Dentistry, a two-year training programme based upon Vedic philosophy of beauty and aesthetics. He maintains a private practice focusing primarily on MI cosmetic dentistry (MICD). Based on more than 17 years of clinical experience in aesthetic dentistry, Dr Koirala developed the Vedic Smile Concept, the Smile Design Wheel, the MICD TP, and various clinical techniques for direct aesthetic restorations. He is the founding president of the Nepalese Academy of Cosmetic and Aesthetic Dentistry and South Asian Academy of Aesthetic Dentistry.



He has published numerous clinical articles in aesthetic dentistry and authored *A clinical guide to Direct Cosmetic Restorations with Giomer*, published by Dental Tribune International GmbH. In addition, Dr Koirala serves as Editor-in-Chief of **cosmetic dentistry**\_beauty & science. He frequently conducts hands-on programmes and delivers lectures globally on smile aesthetics. He can be contacted at skoirala@wlink.com.np.