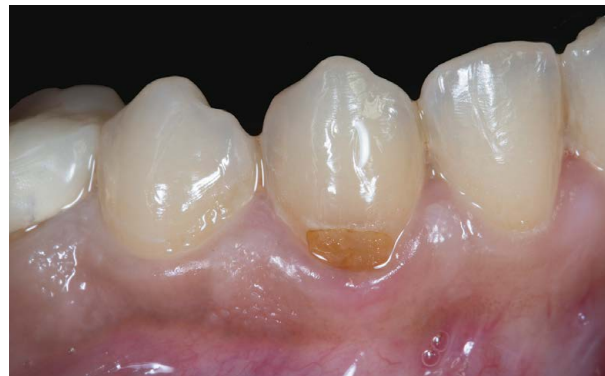
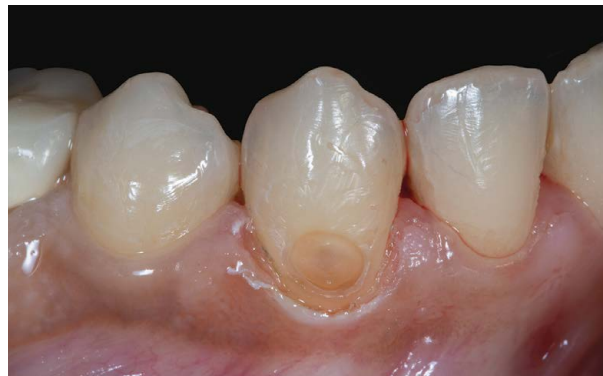
# Class V Restoration with Modification of Anatomy

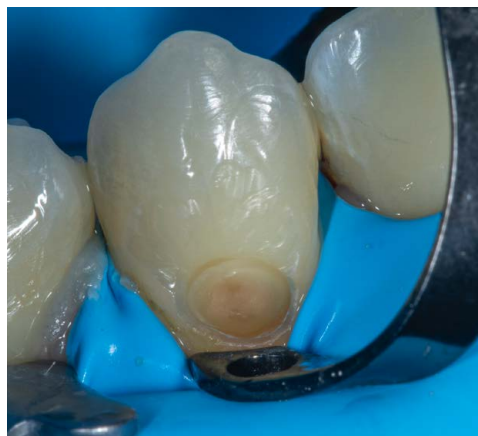40 years old lady visited the dental office for sensitivity on eating sweets and cold on lower canine tooth. Clinical examination revealed cervical decay with slight subgingival extension and some irregularities on the tooth. The MiCD treatment approach with the naturomimetic "ONE layering technique" was adopted for this Class V lesion. After caries removal, crown lengthening with electrocautery was done to create a supra gingival margin with the intension to increase longevity of the restoration followed by a direct restoration with bioactive restorative materials (Shofu Beautifil range of composites). The patient was extremely satisfied with the invisible restoration as the restorative material blended well with the natural tooth.



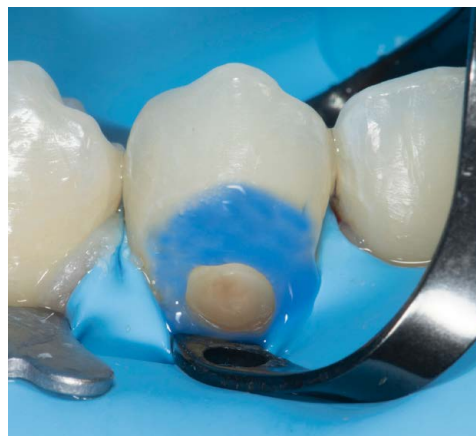1. Retracted view of Class V Decay on tooth #43.



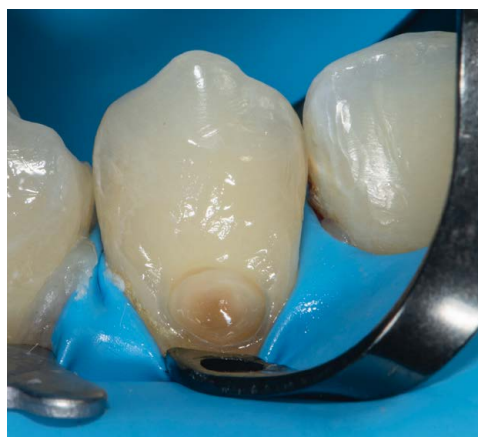2. Retracted view after caries removal, bevel preparation and crown lengthening of tooth #43 to create a supra gingival margin.



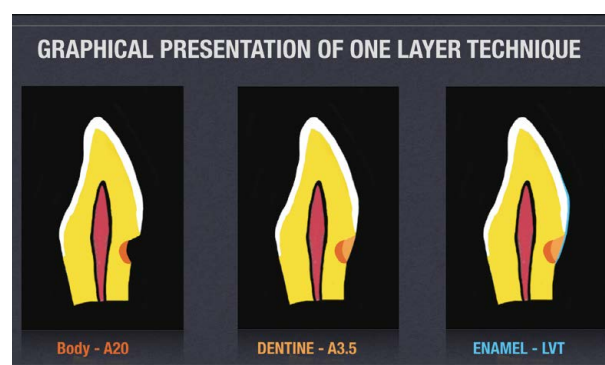
3. Rubber dam placement with B4 wingless clamp.



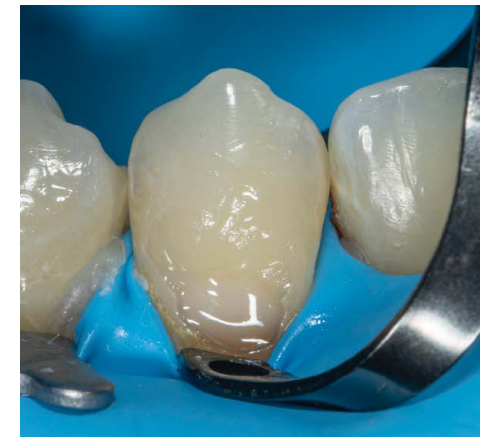4. Selective etching with slight extension above the preparation for modification of tooth anatomy.



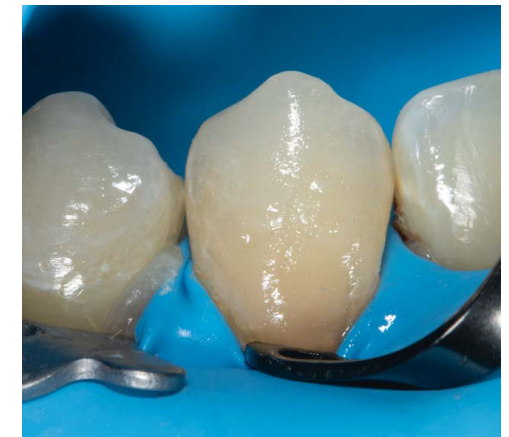5. Application of 6<sup>th</sup> Generation Adhesive system (FL Bond II)



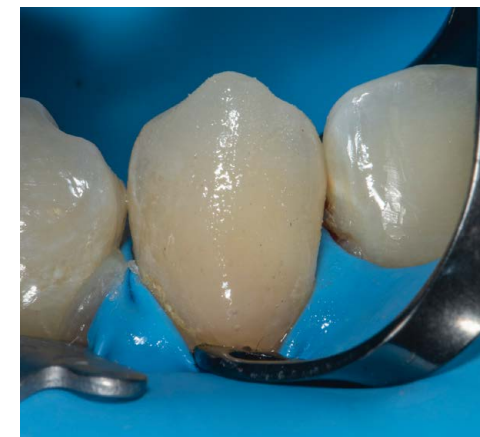6. Illustration of the Naturomimetic "ONE" layering technique using Bioactive Beautifil range of composites (Opaque - Beautifil Injectable A20, Dentin - Beautifil II LS A3.5, Enamel - Beautifil II Enamel LVT)



7. Build-up of deep dentin layer with a small quantity of Beautifil Injectable A20 shade and light cured.



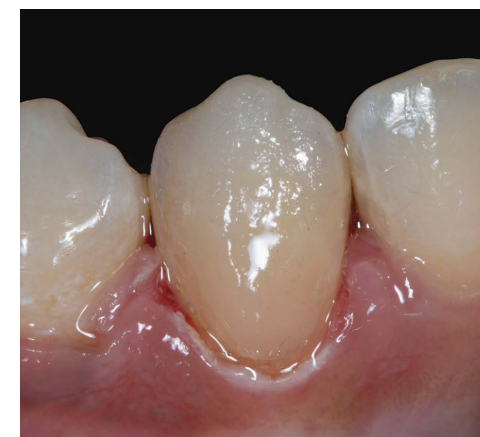8. Build-up of dentin layer with Beautifil II LS shade A3.5 while maintaining 0.3mm for the enamel layer.



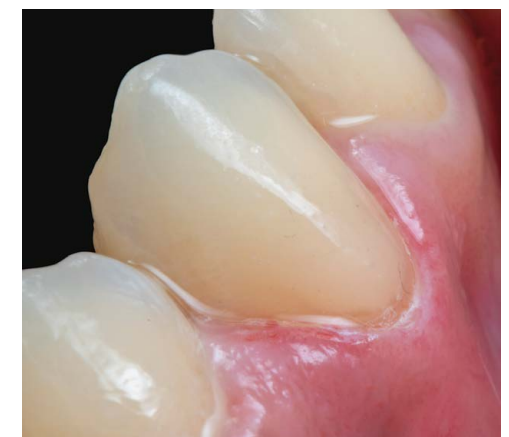9. Final enamel layer placed with low value translucent Beautifil II shade LVT to achieve the desired brightness.



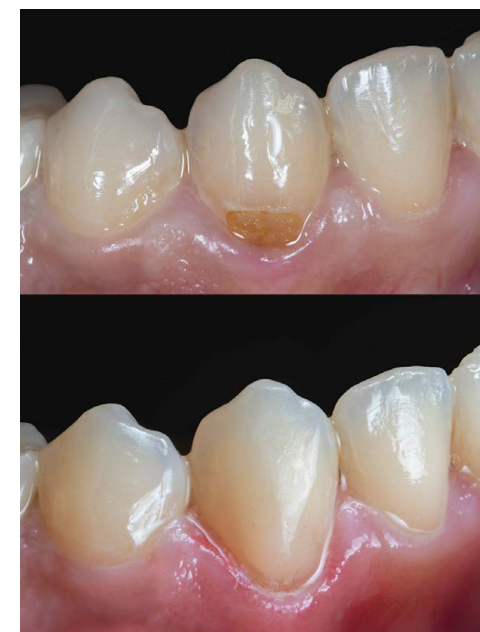10. Application of Glycerine for the final cure to remove the inhibition layer.



11. After removal of rubber dam for anatomical contouring.



12. Finishing and polishing completed Super-Snap X-Treme disk system. (Black disk for contouring, Purple disk for finishing, Green / Pink disks for polishing and super polishing with Aluminium oxide impregnated Super buff disk.



13. Before and After - one-month post-op showcasing life-like aesthetics achieved to mimic the natural tooth.